

## **REPAIR OF MITRAL VALVE USING TRIANGULAR RESECTION OF ANTERIOR LEAFLET & ANNULOPLASTY RING.**

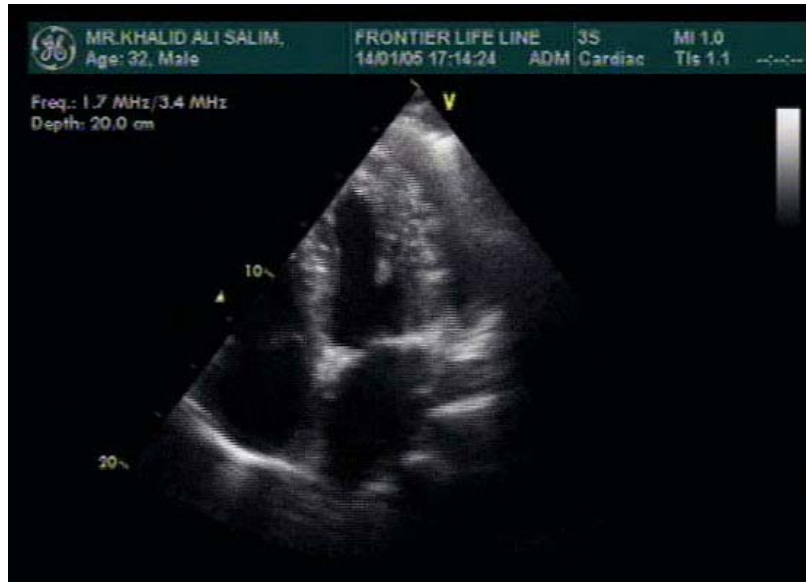### **Introduction :**

In degenerative mitral valve disease, repair of the valve is superior to valve replacement since oral anticoagulation is not required, there is a lower risk of endocarditis & stroke, less mortality at the time of surgery, and they have better long term survival following repair.

Various surgical techniques have been described for the repair of mitral valve with or without using an annuloplasty ring depending upon the pathological changes. Isolated prolapse of the anterior mitral leaflet with severe mitral regurgitation is relatively uncommon compared to prolapse of the posterior mitral leaflet. The technique commonly used is edge-to-edge repair, Chordal transfer and shortening, use of artificial chordae and triangular resection of anterior mitral leaflet . This report describes a case of successful mitral valve repair using triangular resection of anterior mitral leaflet & annuloplasty ring.

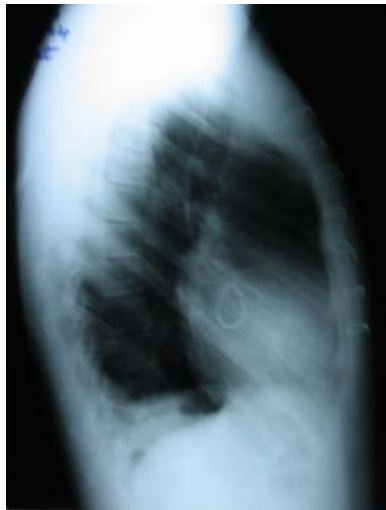### **Case history :**

A 32-year-old male from Kenya was referred to Frontier Lifeline as a case of mitral valve prolapse with severe mitral regurgitation. Clinical examination revealed a holosystolic murmur in the mitral area conducted to the base and axilla. He was in sinus rhythm. 2 Dimensional transthoracic echocardiography and transoesophageal echocardiography revealed a myxomatous mitral valve with severe mitral regurgitation, prolapsing anterior mitral leaflet due to ruptured chordae, & a dilated mitral annulus



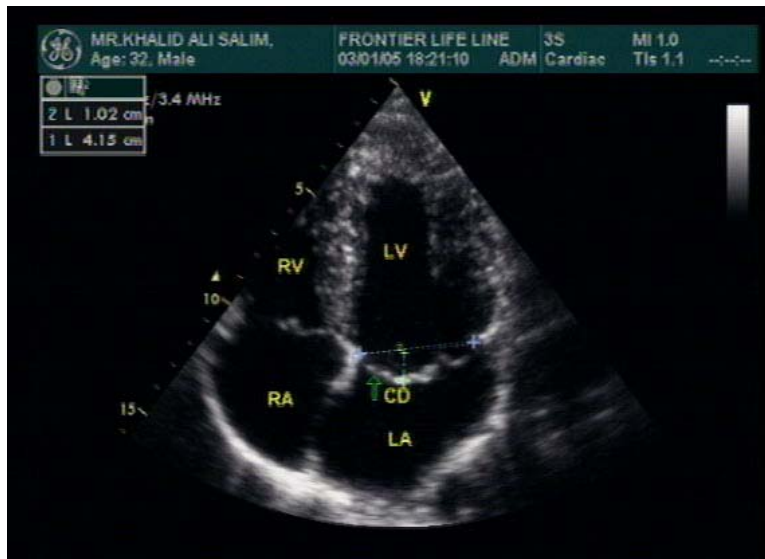
(Fig 1 Postoperative 2 Dimensional echocardiogram showing severe mitral regurgitation).

He underwent mitral valve repair through a complete midline sternotomy using cardiopulmonary bypass. Intra-operatively, after routine left atriotomy, cold saline was carefully instilled into the left ventricle, to identify the prolapsing segment of the anterior mitral leaflet and the area of resection. The segment of anterior mitral leaflet prolapsing into the left atrium was resected, sparing major chordae while keeping clear of the annulus. The free edges of the remaining anterior leaflets were sutured using 3/0 Ticron sutures and the annuloplasty was performed using 32 size Carpentier-Edwards ring



(Fig 2 :Lateral view Xray chest showing the annuloplasty ring)

Intraoperative Transesophageal Echocardiography performed after coming off cardiopulmonary bypass revealed good valvular repair with trivial leak. The postoperative course was uneventful and he was discharged on the 8<sup>th</sup> post-operative day. 2 Dimensional Echocardiography taken just prior to discharge confirmed good coaptation of the valve leaflets with no mitral regurgitation.



(Fig 3 : Postoperative 2 Dimensional echocardiogram show good repair)

#### Comment:

In current clinical practice, majority of the non-rheumatic mitral valve lesions can be repaired successfully employing different techniques including ring annuloplasty, leaflet resection and reconstruction, chordal shortening and chordal transfer. Severe mitral regurgitation with isolated prolapse of the anterior mitral leaflet is relatively uncommon & perceived as an incremental risk factor for reoperation. Anterior mitral leaflet repair is considered technically more difficult and less often successful when compared to repair of a posterior mitral leaflet prolapse. The commonly accepted techniques are chordal transposition<sup>1</sup>, Alfieri technique of edge-to-edge repair<sup>2</sup>, use of artificial chordae and, triangular resection of the anterior mitral leaflet<sup>3</sup>.

Triangular resection of the anterior mitral leaflet was originally described by Carpentier as a part of mitral valve reconstruction. Many studies have shown that anterior leaflet resection is comparable results to other anterior leaflet procedures. Fasol et al<sup>4</sup> describing

their experience with a similar technique in 18 patients out of a total cohort of 339 cases of mitral valve repair, have reported no hospital death, no repair failure requiring valve replacement and no instance of left ventricular outflow tract obstruction due to systolic anterior motion. Totaro et al have reported a 11 year follow up of mitral valve repair for isolated prolapse of the anterior mitral leaflet in 84 patients in which the cumulative freedom from reoperation was 85% at 8 years and 92% of survivors showed nil or trivial regurgitation during the same period. They concluded that in spite of a greater complexity in performing the repair, conservative surgery to correct prolapse of the anterior mitral leaflet is favoured considering the good results in the long term. Successful repair with this technique avoids the use of artificial materials like PTFE as with chordal replacement.

Our observation is that this technique of repairing the mitral valve by triangular resection of the anterior mitral leaflet and an annuloplasty ring, although technically demanding, is an effective alternative to valve replacement.

**Dr.N.Madhu Sankar – Consultant Cardiac Surgeon**

**Dr.G.N.Prasad – Consultant Cardiologist**

**Dr.Sanjay M Cherian – Staff Surgeon**

**Dr.K.M.Cherian – Chief Cardiac Surgeon**